

## Case Report

# Indications and Future Perspectives of a Minimally Invasive Ultrasound-guided Double-needle Joint Lavage

Rajendra Kumar Sahoo<sup>1,2</sup>, Felice Galluccio<sup>2,3\*</sup>, Ke-vin Chang<sup>4</sup>, Mario Fajardo Perez<sup>2,5</sup>

<sup>1</sup>Department of Anesthesiology and Pain Management, Kalinga Institute of Medical Sciences, Bhubaneswar, Odisha, India, <sup>2</sup>Medical-Geriatric Department, Division of Rheumatology, University Hospital AOU Careggi, Florence, Italy, <sup>3</sup>Morphological Madrid Research Center, Madrid, Spain, <sup>4</sup>Department of Physical Medicine and Rehabilitation, National Taiwan University Hospital, Bei-Hu Branch, Taipei, Taiwan, <sup>5</sup>Department of Anesthesia and Reanimation, Hospital Universitario Mostoles, Madrid, Spain

## Abstract

Arthroscopic joint lavage was proposed as a treatment option for different joint conditions such as septic or inflammatory arthritis. Ultrasound (US) is today considered a fundamental tool in musculoskeletal diseases as for diagnostic and guide for interventional procedures such as synovial fluid sampling and drug injections. To enable faster recovery and to have an alternative to surgery, to reduce risks and costs, we performed an US-guided double-needle lavage of the shoulder joint. Here, we present two different clinical cases, the first with septic arthritis and the second with recalcitrant gouty arthritis, successfully treated with this technique.

**Keywords:** Crystal arthritis, joint lavage, septic arthritis, ultrasound-guided intervention

## INTRODUCTION

Joint lavage (JL) was proposed as a treatment option for different joint conditions such as osteoarthritis, inflammatory arthritis, and septic arthritis.<sup>[1]</sup> JL has been performed arthroscopically, to remove joint debris, microcrystals, catabolites, and pro-inflammatory cytokines that cause pain and effusion. It is also indicated in septic arthritis to remove bacteria and purulent material facilitating response to antibiotics and reduce hospitalization times.<sup>[2,3]</sup> Ultrasound (US) is considered a fundamental tool in the management of musculoskeletal diseases, useful both in the diagnostic and as a guide for interventional procedures.<sup>[4]</sup> We present two different cases of shoulder monoarthritis in which a US-guided sampling of the synovial fluid was performed and subsequently treated with US-guided double-needle JL (USG-JL).

## CASE REPORTS

### Case 1

A 71-year-old female presented to our clinic with acute onset of severe left shoulder pain with inability to lift the arm, feeling of fatigue, and a mild rise in body temperature. She rated her

pain 8/10 (Numeric Rating Scale: 0 – no pain and 10 – worst imaginable pain). Her past medical history was complicated by type 2 diabetes mellitus and cerebellar infarct, from which she had completely recovered. Her medications included oral hypoglycemics, aspirin 75 mg/day, pregabalin 50 mg/day, and paracetamol 500 mg twice daily. Physical examination revealed shoulder swelling with severe tenderness and a slight local rise in temperature and a limited range of motion. The sensory examination was normal. US showed glenohumeral joint (GHJ) effusion [Figure 1a and b] and X-ray revealed degenerative changes [Figure 1c]. Laboratory tests revealed elevated erythrocyte sedimentation rate (ESR) (121 mm/h) and C-reactive protein (CRP) – 220 mg/dl (normal <6). Total leukocyte count (TLC) was mildly elevated at 12500/mm<sup>3</sup> (4000–10000) with 84% neutrophils (normal: 40%–80%). Rheumatoid arthritis tests were negative. Suspecting an infection, we performed US-guided sampling, aspirating 14 ml of thick whitish pus [Figure 1d], confirming the diagnosis of

**Address for correspondence:** Dr. Felice Galluccio, SOD Reumatologia, AOU Careggi Ponte Nuovo PAD. 28C - Via Delle Oblate, 4, 50141 Firenze (FI) Italy.  
E-mail: [felice.galluccio@momarc.org](mailto:felice.galluccio@momarc.org)

Received: 17-08-2020 Revised: 29-10-2020 Accepted: 04-12-2020 Available Online: 14-05-2021

### Access this article online

#### Quick Response Code:



**Website:**  
[www.jmuonline.org](http://www.jmuonline.org)

**DOI:**  
10.4103/JMU.JMU\_120\_20

This is an open access journal, and articles are distributed under the terms of the Creative Commons Attribution-NonCommercial-ShareAlike 4.0 License, which allows others to remix, tweak, and build upon the work non-commercially, as long as appropriate credit is given and the new creations are licensed under the identical terms.

**For reprints contact:** [WKHLRPMedknow\\_reprints@wolterskluwer.com](mailto:WKHLRPMedknow_reprints@wolterskluwer.com)

**How to cite this article:** Sahoo RK, Galluccio F, Chang K, Perez MF. Indications and future perspectives of a minimally invasive ultrasound-guided double-needle joint lavage. *J Med Ultrasound* 2021;29:291-3.

septic arthritis. Then, USG-JL with saline was performed until the drainage comes out clear (irrigation with 5 ml aliquots for a total of 30 ml). The patient was put on empirical cefuroxime 1.5 g thrice daily and linezolid 600 mg twice daily. Two days later, the culture showed plenty of pus cells but no growth of microorganisms; however, antibiotics were continued for 7 days. The patient improved with a significant reduction in pain and blood markers. Her TLC came down to 8.08, CRP to 100, and ESR to 80. She was discharged with the advice of a gradual range of motion exercises. At a 2-, 4-, and 8-week follow-up, she has improved range of motion and resolution of acute painful episode.

## Case 2

A 48-year-old man with acute intermittent gouty arthritis came for recurrent swelling of the right shoulder in the last 6 months, with poor response to systemic and local infiltrative methylprednisolone acetate. The patient was being treated with colchicine 1 mg/day, etoricoxib 90 mg/day, and allopurinol 300 mg/day. Laboratory tests showed increased ESR (90 mm/h) and CRP (45 mg/dl), mild leukocytosis (TLC: 11,500/mm<sup>3</sup> with 86% neutrophils), uric acid (5 mg/dl), and low-grade fever during the acute phases. US showed GHJ effusion with hyperechoic specks but without tophi [Figure 2a and b]. Considering the infiltrative therapy, to exclude infection, we performed a US-guided sampling for culture and microcrystal research. Approximately 15 ml of cloudy yellow fluid was aspirated. The culture was negative while polarized light microscopy showed monosodium urate microcrystals [Figure 2c]. For the failure of therapy and the abundant microcrystals [Figure 2d], we perform a USG-JL, to remove as many deposits as possible. A total of 500 ml of dextrose 5% water was irrigated with a closed-circuit system [Figure 2c]. No drugs were administered, and the

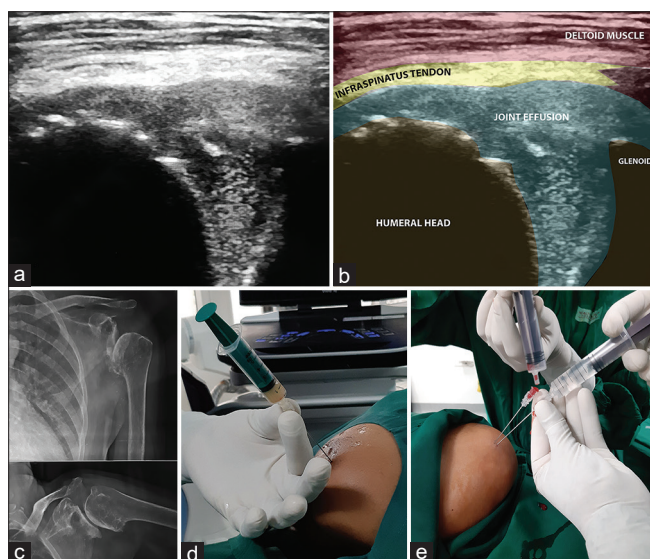
patient was kept on daily allopurinol 300 mg and colchicine 1 mg. The patient experienced a rapid resolution of pain with the recovery of joint mobility in the following days. After a week, the laboratory tests were normalized and the patient was kept on allopurinol only. No relapses at 6-month follow-up were noted.

## Description of the technique

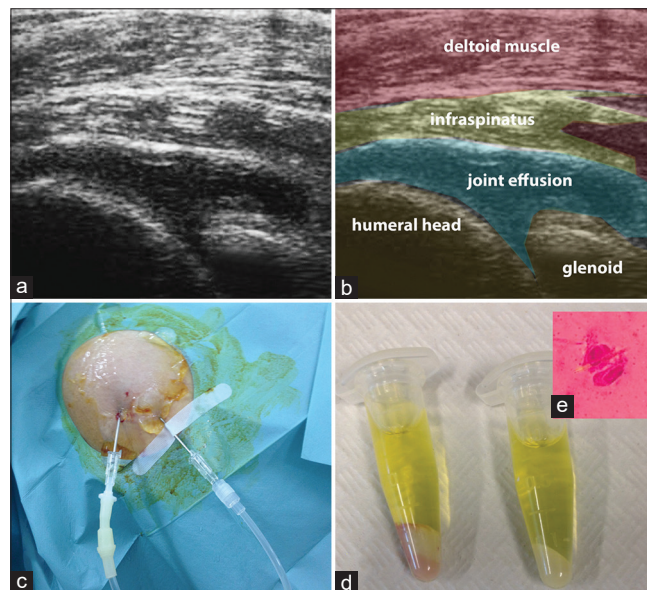
The USG-JL must be performed under sterile conditions, with the patient positioned on the contralateral side with the arm placed under the head. The shoulder is scanned posteriorly to locate the needle's path to the GHJ. High-frequency linear probes are recommended for the best diagnostic performance but also a convex probe can be used. Once the local anesthetic has been injected, the first cannula is inserted in-plane from lateral to medial (14–18G). It is recommended to inject an aliquot of washing fluid so that the overdistension facilitates the positioning of the second cannula, about 1 cm apart. It is possible to choose a one-way closed-circuit system (Case 2) or by injecting washing aliquots (Case 1). The procedure ends when the drainage comes out clear.

## DISCUSSION

The extensive use of US in musculoskeletal conditions allows us to diagnose and treat our patients more precisely.<sup>[5]</sup> In both cases presented, there was joint effusion, with specks, spots, and snowstorms.<sup>[6,7]</sup> The US allowed us to perform the sampling of synovial fluid<sup>[8]</sup> and to directly proceed to USG-JL, simply by placing a second cannula. The USG-JL procedure provided a rapid reduction of pain and inflammation which facilitated rehabilitation and therefore a rapid hospital discharge. This procedure therefore ensured savings in health care costs when



**Figure 1:** Case 1. (a and b) Ultrasound appearance of glenohumeral joint effusion; (c) X-ray; (d) aspiration of infective material after ultrasound-guided in-plane needle positioning; (e) discontinuous joint lavage with 5 ml aliquots



**Figure 2:** Case 2. (a and b) Ultrasound appearance of glenohumeral joint effusion; (c) continuous double-needle joint lavage; (d) urate deposits in synovial fluid samples; (e) monosodium urate microcrystal at polarized compensated light microscopy

compared to the standard arthroscopic lavage procedure or prolonged pharmacological treatment. In both cases presented, there were no relapses, despite the pharmacological treatment being maintained for <10 days. In the first case, clinical and laboratory findings led us to an infectious cause and traditionally joint infections are surgically treated.<sup>[9]</sup> Magnetic resonance imaging probably provides better soft-tissue resolution but is time-consuming and expensive than the US. Moreover, US allows real-time visualization, precise needle placement, avoidance of radiation exposure and damage to the surrounding neurovascular structures.<sup>[4]</sup> To the best of our knowledge, this USG-JL has not been described in the literature. Upon review, we could find a case report of percutaneous catheter drainage for septic shoulder joint done under the landmark technique,<sup>[10]</sup> where landmark-guided JL was described for the knee joint.<sup>[1]</sup> This technique does not guarantee complete washing of the joint, as studies are still ongoing. Another key point is that, with both techniques presented, the amount and pressure of the flushing fluid are low, avoiding any rupture of the joint capsule.

To conclude, percutaneous USG-JL can avoid surgery and provide faster recovery and discharge from the hospital, or it can be offered as an alternative when surgery is not accessible or contraindicated.

#### Declaration of patient consent

The authors certify that they have obtained all appropriate patient consent forms. In the form, the patients have given their consent for their images and other clinical information to be reported in the journal. The patients understand that their names and initials will not be published and due efforts will be made to conceal their identity, but anonymity cannot be guaranteed.

#### Financial support and sponsorship

Nil.

#### Conflicts of interest

Dr. Ke-vin Chang, an editorial board member at *Journal of Medical Ultrasound*, had no role in the peer review process of or decision to publish this article. The other authors declared no conflicts of interest in writing this paper.

#### REFERENCES

1. Ayral X, Dougados M. Joint lavage. *Rev Rhum* 1995;62:281-7.
2. Shirliff ME, Mader JT. Acute septic arthritis. *Clin Microbiol Rev* 2002;15:527-44.
3. Dodwell ER. Osteomyelitis and septic arthritis in children: Current concepts. *Curr Opin Pediatr* 2013;25:58-63.
4. Hansford BG, Stacy GS. Musculoskeletal aspiration procedures. *Semin Intervent Radiol* 2012;29:270-85.
5. Lamers-Karnebeek FB, Van Riel PL, Jansen TL. Additive value for ultrasonographic signal in a screening algorithm for patients presenting with acute mono-/oligoarthritis in whom gout is suspected. *Clin Rheumatol* 2014;33:555-9.
6. Lu CH, Li KJ. Snowstorm appearance of synovial fluid on musculoskeletal ultrasound. *J Med Ultrasound* 2019;27:119-20.
7. Persons B, Kissin EY. Scruples over speckles. *J Med Ultrasound* 2020;28:179-80. Available from: <https://www.jmuonline.org/preprintarticle.asp?id=285047>. [Last accessed on 2020 Aug 12].
8. Jiang JJ, Paponov HI, Mass DP, Angeles JG, Shi LL. Septic arthritis of the shoulder: A comparison of treatment methods. *J Am Acad Orthop Surg* 2017;25:e175-84.
9. Li R, Lu Q, Chai W, Hao LB, Lu SB, Chen JY, *et al.* Saline solution lavage and reaspiration for culture with a blood culture system is a feasible method for diagnosing periprosthetic joint infection in patients with insufficient synovial fluid. *J Bone Joint Surg Am* 2019;101:1004-9.
10. Sanders TR, Staple TW. Percutaneous catheter drainage of septic shoulder joint. *Radiology* 1983;147:270-1.